

Handwritten: Exhibit 412
11. 524-77

EXHIBIT
118

DEFENDANT'S
EXHIBIT
B-23

Handwritten signature/initials

geneem word dat die middels wat die pyn verlig die sirkulasie in die kroonslagare verbeter. Dit moet ook aangeneem word dat, aangesien die nitriete gladde spiere laat ontspan (insluitende spiere van die slagaarstelsel), hulle (die nitriete) hartkramp verlig deur spasme van die kroonslagare op te hef. Al hierdie oorwegings is waarskynlik korrek, maar nie een van die aannames is bewys nie, aangesien geen direkte waarneming gemaak is van die kroonslagare gedurende 'n aanval, met spesiale verwyding tot die uitwerking van nitriete nie.

By miokardiale infarksie ontwikkel pyn in sy ergste vorm as gevolg van hipoksie van die miokardium. Die pyn is weerstandig vir verwyders van die kroonslagare en is moeilik om te verlig, selfs deur die gebruik van sulke pynstillende middels soos morfien.

Die middels wat gebruik word vir verwyding van die kroonslagare is betreklik non-spesifiek. Die nitriete laat alle gladde spiere ontspan, maar die arteriole is meer vatbaar vir hierdie uitwerking. Dit mag wel wees dat hulle slegs 'n betreklike spesifieke uitwerking het in gevalle van abnormale vatbaarheid, soos byvoorbeeld by spasme van die kroonslagare, waar klein dosisse verligting bring sonder dat daar 'n algemene gestelsuitwerking is. Dit veronderstel dat die middels weinig waarde mag hê vir die verbetering van kroonslagaar-sirkulasie as daar geen spasme is nie. 'n Middel wat 'n vinnige uitwerking het, is aangewese; en as die pyn eers verdwyn, skyn geen verdere medisyne nodig te wees nie. Dit mag dus gebeur dat, by die gebruik van vatverwyders wat 'n verlengde uitwerking het, die pyn reeds al deur rus verlig word voordat die farmakologiese uitwerking van die middel kan intree; ook kan die uitwerking van die middel dan nog lank voortduur nadat daar nie meer behoefte daarvoor is nie. Vir die verligting van 'n aanval van hartkramp is die soort middel wat 'n vinnige uitwerking het, aangewese. Daar is baie middels wat 'n stadige uitwerking het, (wat gebruik word om aanvalle te voorkom of om 'n langdurige uitwerking teweeg te bring), wat slagare wat in spasme is gou laat ontspan en die pyn dus verlig feitlik voordat dit ontwikkel. Daar is egter geen afdoende antwoord op hierdie probleem nie — in die literatuur is daar baie teensprekende verklarings oor hierdie saak. Verskeie ondersoekte op hierdie gebied is of swak beplan of onvoldoende gekontroleer.

Die nitriete het 'n kragtige uitwerking om die akute aanval van hartkramp te verlig. Gliserieltrinitraat (in tabletvorm) is gewoonlik die beste. Amielnitriet is nie meer amptelik (B.P.) nie, maar word tog nog aanbeveel wanneer 'n baie vinnige uitwerking verlang word. Gliserieltrinitraat wat ingesluk word (nitro-gliserien) is waardeloos, aangesien die middel in die lewer vernietig word. Die uitwerking word van krag as die middel onder die tong opgeelos word; dit neem 'n rukkie langer om opgemerk te kan word, maar dit duur ook weer langer as wat die geval is met nitriete wat ingesem word. Die middel het 'n vaste dosievorm en word dus deur die geneesheer en nie deur die pasiënt nie, bepaal. Dit is ook veilig om te gebruik as die geneesheer nie teenwoordig is nie. Daar is verskillende middels in hierdie 'nitraat' groep wat 'n langdurige uitwerking het, maar hulle word nie baie algemeen gebruik nie.

'n Groot groep middels wat teenhouers is van monoamien oksidase (iproniasied, isokarboksasied, fenel-sien, nialamied) het nou verskyn. Hulle het 'n uitwerking op die luim van die pasiënte — die sogenoemde, psigiese energieverwekkers. Sommige hiervan mag wel van waarde wees by die behandeling van hartkramp, maar die hele aangeleentheid behoort versigtig benader te word. Aminofillien en teobromien word 'n geruime tyd lank al gebruik vir hartkramp, maar, soos dit ook die geval is met so baie ander middels, het 'n vergelyking met die gebruik van plasebo's geen spesiale voordeel aangedui nie.

Alhoewel daar dus 'n hele aantal middels is wat wel 'n uitwerking het op hartkramp, is die nitriete die enigste middels waarop ons kan reken dat hulle die kroonslagare verwyd en pyn verlig. Dit is nie bewys dat die meeste ander middels wat hierdie uitwerking sou hê, wel effektief of betroubaar is nie. Die nitriete het egter nie 'n voorbehoedende uitwerking nie, miskien omrede van die ontwikkeling van toleransie. Die groot behoefte op hierdie gebied is eintlik aan 'n middel wat aan 'n ander farmakologiese groep behoort, en waarteen toleransie nie ontwikkel nie.

1. Modell, W. (1960-1961): *Drugs of Choice*. St. Louis: C. V. Mosby.

DIFFUSE PLEURAL MESOTHELIOMAS IN SOUTH AFRICA

C. A. SLEGGs, *Medical Superintendent, West End Hospital, Kimberley;*
PAUL MARCHAND, *Department of Thoracic Surgery, University of the Witwatersrand and Johannesburg General Hospital; and*
J. C. WAGNER, *Senior Medical Officer, Pathology Division, Pneumoconiosis Research Unit, South African Council for Scientific and Industrial Research, Johannesburg*

In another paper¹ we reported on 33 cases of diffuse pleural mesothelioma, histologically diagnosed at the Pneumoconiosis Research Unit of the South African Council for Scientific and Industrial Research, Johannesburg. Thirty of the cases were investigated clinically by ourselves. Since then a further 8 cases have been proved, 4 of which were under our care. This paper supplements our other communication with a description of the clinical

and radiological findings in the 34 cases which we ourselves investigated.

COMPARATIVE RARITY OF DIAGNOSIS

The histological diagnosis of diffuse pleural mesotheliomas is a contentious subject. Doubt has been thrown on their existence as an entity by Robertson² and Willis.³ Primary malignant mesothelial tumours were described by

Kle
ref
var
Bel
nos
pat
the
anu
' l
rar
34
tal
the
cas
lar
ye
in
his
nu
on
m:

Ti
is
m
be
(3
in
w
th
ir
c
o
n

a
e
t

akute
at (in
is nie
beveel
1.
a)
lewer
as die
rukkie
k weer
word.
eur die
is ook
oordig
nitraat
e word

is van
fenel-
uitwer-
noemde,
wel van
naar die
word.
lank al
geval is
met die
angedui

wel 'n
enigste
nslagare
meeste
ek-
'n
van die
hierdie
n ander
ansie nie

t. Louis:

neral

Council

we our-

theliomas
on their
Primary
ribed by

Kiemperer and Rabin⁴ and Stout and Murray.⁵ Recently reports concerning these tumours have appeared from various countries; these include those of Tobiasen,⁶ Bellini and Bovo,⁷ Godwin⁸ and McCaughey.⁹ The diagnosis in our cases has been confirmed by South African pathologists and well-known authorities from Britain and the USA, including Dible,¹⁰ Gough,¹¹ Steiner,¹² Stewart,¹³ and Vorwald.¹⁴

Diffuse pleural mesothelioma is generally considered a rare tumour. Daub and Jones¹⁵ reported 3 cases among 345,000 consecutive admissions to the Henry Ford Hospital. The largest series that we have been able to find in the literature is that of Choptal *et al.*¹⁶ who described 22 cases seen over a period of many years. In contrast, our larger group has been diagnosed mainly during the last 4 years. It must be stressed that we have only included cases in which the nature of the tumour has been confirmed histologically, either on biopsy or necropsy material. A number of cases showing radiological and clinical features only have been excluded. Three of these cases had markedly abnormal cells in the pleural fluid.

ASSOCIATION WITH ASBESTOS

This frequency of mesotheliomas is possibly significant in its apparent association with areas where asbestos is mined or milled. Evidence in support of this has already been presented¹ and includes:

1. The finding of asbestos bodies in the lungs of 12 (30%) of the 41 patients with mesotheliomas, even though in the majority of the earlier cases, before the association was suspected, the biopsies usually consisted of tissue from the parietal pleura only. Asbestos bodies have been found in 9 of 11 biopsies in which lung parenchyma was included. Evidence of asbestosis has been observed in 6 out of the 7 cases in which the lungs have been examined at necropsy.

2. The fact that 19 of these patients worked with asbestos, either as miners, millers or industrial workers.

3. The fact that all except 2 of the other 22 cases were either born, or spent a significant period of their lives, in the asbestos area of the north-western Cape Province.

Asbestos Bodies in the Sputum

Further, one of us (C.A.S.), working on the clinical hypothesis that exposure to asbestos causes an increased pleural reaction in patients suffering from tuberculosis, submitted numerous sputa from the West End Hospital, Kimberley, to the Pneumoconiosis Research Unit for examination. Asbestos bodies and fibres were found in the sputa of 115 patients who had no definite mining exposure. Included in these were specimens from people working in a dry-cleaning works and abattoirs in the North West Cape in places 100 miles away from the nearest mines.

The presence of asbestos bodies and fibres in the sputum is naturally only indicative of exposure to asbestos dust and is not evidence of asbestosis unless there is clinical and radiological support. However, from these findings it would appear that people possibly not associated with asbestos production or utilization, have been exposed to the hazard.

Asbestos in the North West Cape

The area of the asbestos deposit in the North West

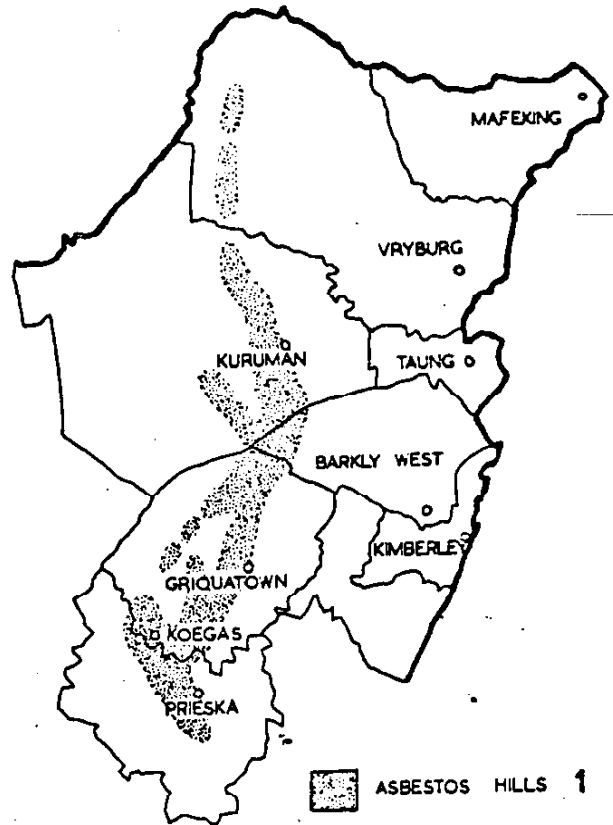


Fig. 1. Map showing asbestos deposits in the Cape Province.

Cape, the most extensive in the world, extends from 20 miles south of the Orange River north to the Bechuanaland border, covering approximately 8,000 square miles. The deposits are mainly in the slopes of the Asbestos Mountains, a range extending more or less longitudinally between 22°30' and 23°E (Fig. 1).

Mining and Milling

The type of asbestos mined throughout this area is crocidolite, better known as Cape blue asbestos. Crocidolite is the fibrous form of riebeckite. All stages of transformation, from massive riebeckite rock through lamellar riebeckite to asbestiform crocidolite, occur in this region. Magnetite is frequently associated with the crocidolite (Vermaas¹⁷). Mining of asbestos first began in the Prieska district in 1893 and gradually spread northward. In 1908, production had begun in the Kuruman district. This northward trend has continued and, in about 1950, mining started at Pom-Pom, near the Bechuanaland border. (Fig. 2 shows, graphically, the asbestos production from 1910 - 1958.) Initially the ore was quarried in numerous small open-cast workings. This was followed gradually by a type of shallow mining; inclined shafting became more common after 1930.

Since the 1939 - 1945 war, the demand for crocidolite has increased enormously. Since deeper and richer deposits have been found, vertical shafts are being sunk. However, the mines with large shallow deposits continue to use the inclined shaft and tunnel, and quarrying is still used by

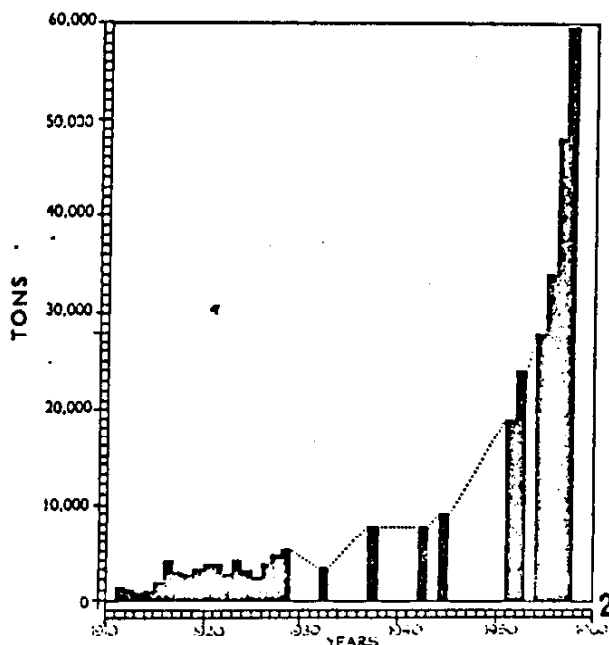


Fig. 2. Production of crocidolite by asbestos mines in the North West Cape in tons per year (1910-1958).

the few remaining smaller producers. With the building of more mills, hand cobbing* has diminished. In 1915 the first crushing mill was established at Koegas in the south. This was followed by a large mill at Kuruman (operated between 1926 and 1931) where it was situated within 300 yards of the main street, close to which hand cobbing was also done for a few years (1927 - 1930). This was followed by a mill at Prieska in 1930, which was completely rebuilt in 1957. Griquatown had a small mill in 1928. The practice today is for one mill to serve several mines in the immediate vicinity.

In the early days the manager and labourers lived within a few yards of their place of work, and even today the non-White personnel prefer to live as close as possible to the mills and the children play on the dumps from the mines and mills.

The industrial use of asbestos has increased during the last 30 years. In 1930 Hall stated that there were 4 firms in the Union manufacturing asbestos products (in Cape Town, Durban, Johannesburg and Meyerton) which used a total of 900 tons of fibre annually. In 1952, 17,000 tons of fibre were used in local industry. Carroll-Porczynski¹⁹ lists 7 firms dealing with asbestos in Cape Town and 44 in Johannesburg. Asbestos cement and an asbestos clay compound are used extensively for insulating boilers in power stations, industries and railway locomotives. Three of our patients were employed in this way. Another patient was employed manufacturing fire-proof clothing. Cases of asbestosis have been observed in a variety of industries on the Witwatersrand.

Asbestos and Carcinoma

The association of asbestos with carcinoma of the lung was first described by Lynch and Smith in 1935.²⁰ By

* Freeing the fibre from the ore by striking the lumps of rock with a hammer.

1955, according to Doll,²⁰ a total of 61 cases had been reported. Merewether²¹ analysed the cases that had occurred in Britain between 1924 and 1954. He found that in a total number of 344 cases, carcinoma of the lung was present in 55 (16%), the figure for males being 41 (20% of males) and for females 14 (10% of females). Six cases of mesothelioma of the pleura associated with asbestosis have been described. One was mentioned by Doll,²⁰ 2 by Cartier²² and 3 by Van der Schoot.²³ A further 33 cases with possible asbestos exposure were described by Wagner *et al.*¹

In our series of cases the latent period, between first apparent exposure to asbestos dust and the initial symptoms of the disease, was between 20 and 60 years. In some cases the patients had left the North West Cape and, in others, the exposure had been of such a transitory nature that it was rapidly forgotten. Evidence of exposure was only obtained after long and detailed questioning. According to Day²⁴ and Stewart,²⁵ a long latent period between initial exposure and the development of evidence of malignancy is one of the features of occupational tumours. The reason for the tumours having been found in the vicinity of the Cape asbestos fields and not in the region of the Transvaal asbestos mines may be due to this time factor, assuming that the association is significant, since the industry was established earlier in the Cape than in the Transvaal, where large-scale mining began comparatively recently. The type of asbestos mined is another possible factor which would apply to the chrysotile mines of the Eastern Transvaal. However, the amosite fibre found in the Lydenburg district is similar to the Cape crocidolite and the crocidolite mined around the Pietersburg district is identical.

CLINICAL PICTURE OF MESOTHELIOMA

Clinical Presentation

The majority of patients are over the age of 40, and usually present with symptoms suggestive of a primary tuberculous effusion. Pain varies from a feeling of heaviness to acute pleuritic pain. From the beginning or after a variable time there may be increasing dyspnoea on exertion. Cough is not a predominant symptom in this group. A few patients present as cases of acute respiratory infection with a productive cough. This is accompanied by a pleural effusion. In some cases there is an interval between the respiratory infection and the finding of the pleural effusion. The course of the disease, while ultimately similar, usually takes one of two forms — either the pleural effusion continues to increase, requiring frequent paracentesis, or it undergoes a temporary quiescent period, while the pleural space becomes obliterated by tumour. Towards the end the patient is seriously disabled through pleuritic pain and dyspnoea. Terminally ascites may develop due either to peritoneal metastases or to cardiac failure.

Clinically the disease may be described as having 3 stages. Initially the presentation is one of pleurisy and bronchitis and the usual diagnosis is a virus or pyogenic pneumonitis. At this stage antibiotics are usually successful in alleviating the symptoms. The second stage is one of

pleural effusion with pleural thickening; it is then that the patient is usually admitted to hospital for investigation. Tuberculosis, malignancy, asbestosis and other causes of pleural disease may be considered. The final stage is one of obvious thoracic malignancy.

Age, Sex, Race, Habitat and Occupation

Our 34 cases consisted of 24 males and 10 females (Table 1). Six men who had lived all their lives in the vicinity of the asbestos mines were the only patients under 40 at the time of diagnosis. Four of them had been miners. They

TABLE 1. AGE AND RACE DISTRIBUTION OF THE 34 CASES OF MESOTHELIOMA DESCRIBED

Race	Sex	Age				Total
		30-39	40-49	50-59	Over 60	
White	Male (14)	2	6	3	3	20
	Female (6)	0	1	3	2	
Coloured	Male (5)	2	2	0	1	8
	Female (3)	0	2	1	0	
Bantu	Male (5)	2	2	0	1	6
	Female (1)	0	0	1	0	
Total		6	13	8	7	34

were all in their thirties, the youngest being a miner aged 31. On the other hand, 7 patients were over 60, 5 being men and 2 women. The oldest was a man of 68. Six of these patients had lived for many years in the asbestos area and 3 of the 5 men had worked for long periods in close contact with asbestos. One woman died at the age of 60. As far as we have been able to ascertain, she had never been in contact with asbestos in her occupation as a nursing sister, and had never lived in the North West Cape. She is the only patient of the 34 who apparently had no contact whatever with asbestos.

The remaining 21 patients, 8 women and 13 men, were aged between 40 and 60. The 8 women had either been born in the asbestos district, or had moved there in early childhood. At the time of diagnosis, 3 of these women lived in the Transvaal and had never, or only occasionally, visited the North West Cape after leaving school. Three women had been engaged in the cobbing of asbestos in their homes. The non-European women mostly lived close to mines in houses where cobbing operations produced much dust, even when they themselves had done no such work. The European women had been to school near mills or had played on the dumps.

The 13 men aged between 40 and 60 comprised 7 whose work was connected with the mining, milling and transport of asbestos, 2 who were born and bred in the district but had not been engaged in the industry (they had often watched cobbing operations in native huts and had played on dumps and in mine shafts on farms), and 4 who worked with asbestos in distant industrial towns. Of these industrial cases, 2 were boiler makers who had lagged locomotive boilers. Another of these men had spent the war years manufacturing asbestos protective devices for fighting aircraft fires, and the fourth had worked as a boiler maker in a Cape factory, whose supply of asbestos was obtained from the Cape asbestos fields. It is interesting to note that in 1 family both the father and a daughter died of histologically proved mesotheliomas. In 2 other cases a sibling had radiological evidence of asbestosis.

Physical Signs

In the early stages auscultatory evidence of pleurisy, bronchitis, or consolidation are usual. As the disease progresses, respiratory excursions diminish until eventually a frozen chest results, with flattening of the infraclavicular region, 'roof-tiling' of the ribs and immobility of the chest wall. The chest is then stony-dull to percussion and air entry is grossly impaired.

During this late stage of the disease, evidence of secondary spread may appear. Eight cases in our series showed obvious clinical signs of peritoneal involvement before death. The peritoneum is usually infiltrated by direct spread through the diaphragm. The liver may be enlarged and nodular, due to perihepatic involvement. Localized masses due to involvement of the omentum or para-aortic lymph nodes may be felt. In these cases ascites is common. Involvement of the lymph glands of the neck has been clinically obvious in 2 cases. Implantation of the tumour in a biopsy scar is not frequent, but it complicated 4 thoracotomies and 1 thoracoscopy in our series. Haematogenous spread is unusual and only 2 cases have eventually developed distant metastases. These were predominantly subcutaneous but, in 1 instance, numerous small deposits appeared in the tongue.

Pleural effusions have always developed. Fluid collections of 5-6 pints have occurred, but often the pleural space is largely obliterated and only small effusions can collect. On tapping these effusions, considerable resistance is encountered due to the thickness of the diseased tissue (up to 2 cm.) which has to be traversed. Even with the point inside the cavity, the needle is often so tightly gripped that manipulations are restricted. Usually the fluid is straw-coloured, but blood-staining occurs and may be heavy.




Fig. 3. Diffuse pulmonary asbestosis, particularly well shown in lower lung zones.

SPECIAL INVESTIGATIONS

Radiological Features

The X-ray findings roughly parallel the clinical progress. The initial radiographs may show few changes. In about a third of the cases, radiological signs of asbestosis were present. Asbestosis, in individuals with a proved and adequate record of exposure, is characterized by evidence of diffuse interstitial fibrosis of varying degree. In a well-established case the appearance will conform to the well-known classical pattern of pulmonary asbestosis. This may be either a generalized homogenous clouding of the lung fields, particularly the lower zones, or a fine striate and fibrillary change in the lung structure, with progressive loss of pulmonary radiolucency (Fig. 3).

In the majority of cases of asbestosis, old-standing pleuritic changes are also seen. Thus a combination of both pleural and pulmonary parenchymal pathology frequently occurs. The pleural changes take the form of bilateral pleural thickening, pleural adhesions and rather characteristic dense calcific plaques (Frost *et al.*²⁵). While pleural thickening *per se* in asbestosis is non-specific in character, sclerotic pleurisy, with plaque formation, constitutes a readily recognizable and rather typical entity (Fig. 4). The pattern of calcification patently differs from

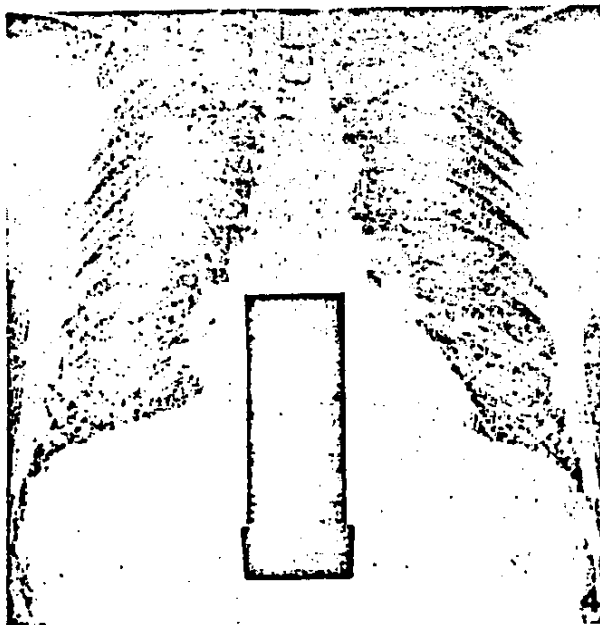


Fig. 4. Extensive bilateral pleural plaque formation. Typical involvement of paramediastinal and diaphragmatic pleura is also demonstrated.

pleural calcification due to other causes. This pattern was recognized frequently during the recent investigations of miners and millers. Even the chance finding of such typical calcification is now accepted as being highly significant, so that previous exposure to asbestos may be predicted with reasonable confidence. The dense plaques, however, do simulate those described in workers exposed to other silicate dusts such as tremolite tale, calcining and

mica (Smith²⁶). The plaques may be few or widespread. They are usually bilateral, and disposed in irregular patches, chiefly in the middle and lower zones. Seen end on they appear as linear plaques in the periphery, along the diaphragmatic contours, and adjacent to the mediastinum. A lateral view of the thorax will also very often show extensive linear plaque formation, involving the diaphragm and the anterior aspect directly behind the sternum. Such pleural calcification was encountered in several of our cases of mesothelioma (Hurwitz^{27,28}).

However, in the majority of cases, no evidence of preceding pleural or pulmonary asbestosis was found. These cases, on investigation, invariably showed unilateral pleural involvement in the form of diffuse thickening or effusion. The appearance may be massive from the beginning, but usually a localized scalloping, or solitary mass in the periphery, raises the first suspicion of pleural neoplasm. As the disease advances, more extensive nodular or 'lumpy' pleural thickening develops (Fig. 5). This pattern

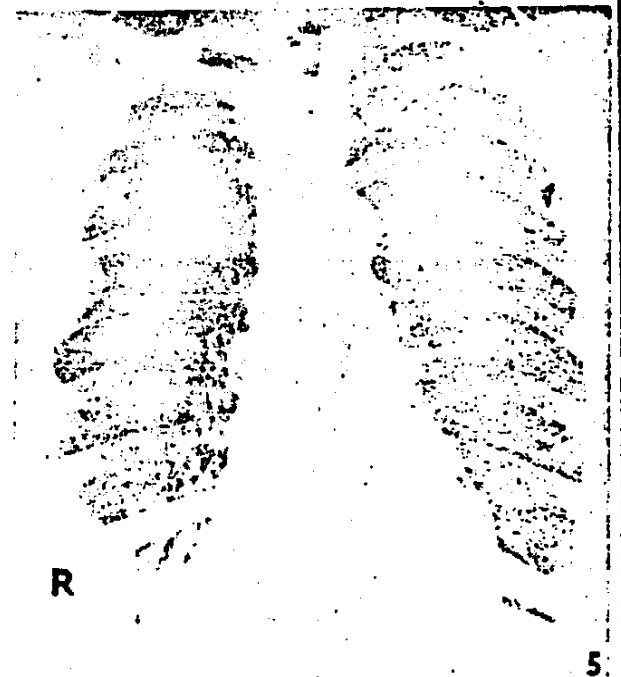


Fig. 5. Nodular pleural thickening, seen clearly on the right.

of unilateral pleural pathology is a highly significant finding in a patient from the asbestos areas, but of course, a similar appearance may be produced by secondary malignant involvement of the pleura. Very often a large pleural effusion will obliterate the picture and, only after removal of the fluid, will it become apparent that the pleura is grossly thickened and nodular. Both the parietal and visceral pleura are affected and an induced pneumothorax, particularly, will clearly demonstrate the rather characteristic pattern of marginal massive nodularity along the parietal chest wall, over the surface of the collapsed lung, and at the base (Fig. 6).

14 Januarie 1961

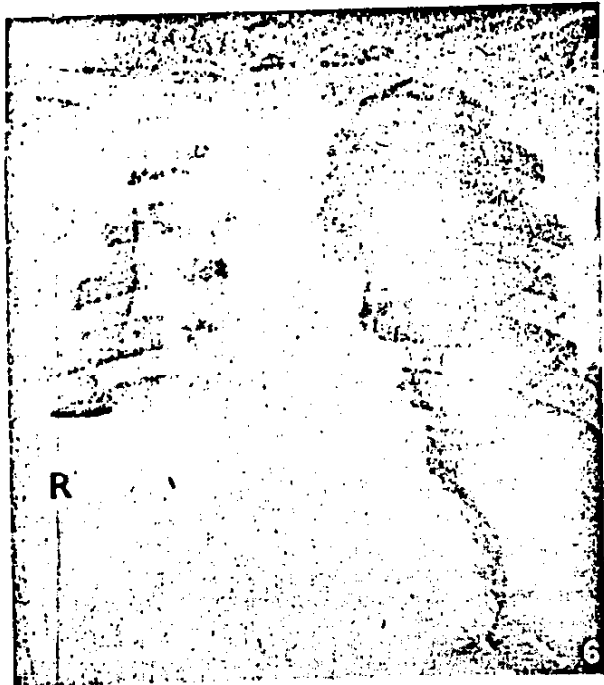


Fig. 6. Induced pneumothorax revealing gross malignant involvement of pleura. A considerable quantity of fluid is still present in the right pleural cavity.

In the later stages, a considerable part of the pleural cavity may be obliterated and a comparatively small space may remain. Here fluid may collect under tension and the lung may be further compressed, in spite of being encased by a thick tough covering of malignant tissue. As the mediastinal pleura thickens, and the regional lymph glands become infiltrated, widening of the mediastinum is seen radiologically. Eventually the pericardium is involved by direct extension, and the resultant pericardial effusion causes progressive enlargement of the cardiac silhouette and a change in its configuration. Extrapleural extension can also occur; then radiological evidence of rib involvement may be present.

Stout and Murray⁵ remark upon the right-sided preponderance of the disease. In the series of 24 cases reported by Choptal *et al.*¹⁶ 19 were right-sided. Our cases present an identical distribution, since 27 of the 34 cases had right-sided lesions. In no case was the mesotheliomatous process initially bilateral, although the X-rays of 10 of the patients showed bilateral changes due to asbestosis.

Thoracoscopy and Thoracotomy

The information obtained from thoracoscopy was disappointing. The view is always limited in cases of mesothelioma because the cannula cannot be freely manipulated. When blood has extravasated into the effusion, the walls of the cavity are covered with fibrinous deposits and no architectural details are visible. The chief objection to the technique, as a diagnostic measure, is that the choice of area for biopsy is restricted, and it is impossible to obtain a representative specimen. Thoracoscopy was the usual diagnostic procedure in the early stages and, al-

though sufficient material for microscopic examination was usually obtained, we feel that a great deal of information was missed.

With early cases, where the pleura is thin and the effusion clear, it is often possible to visualize the discrete pleural nodules overlying the still elastic lung. The nodules are then usually cherry-coloured and either smoothly-rounded or warty in appearance. Later the discrete nodules coalesce and the underlying lung is obscured. The growth is then usually seen as a grey opaque membrane, with localized excrescences of variable size and similar appearance projecting into the pleural space. At this stage the outstanding feature is the thickness and density of the pleural growth and the complete immobility of the incarcerated lung beneath.

As far as possible, it is now our policy to obtain a specimen of lung by open operation. With 4 early cases, attempts were made to decorticate lungs which were completely encased by thick, apparently fibrous, coverings. In 3 cases the findings were similar. The parietal pleura was 1 - 2 cm. thick and very hard. The lungs were collapsed and bound down by thickened visceral pleura, identical in appearance with the parietal pleura. The pleural spaces were occupied by straw-coloured or blood-stained fluid. Attempts to strip the "peel" off the chest wall could only be made through the extrapleural plane, but even then the intercostal spaces were constantly entered and no vestige of normal parietal pleura could be found. Calcified plaques within the diseased tissue were frequently encountered, particularly over the diaphragm and inter-

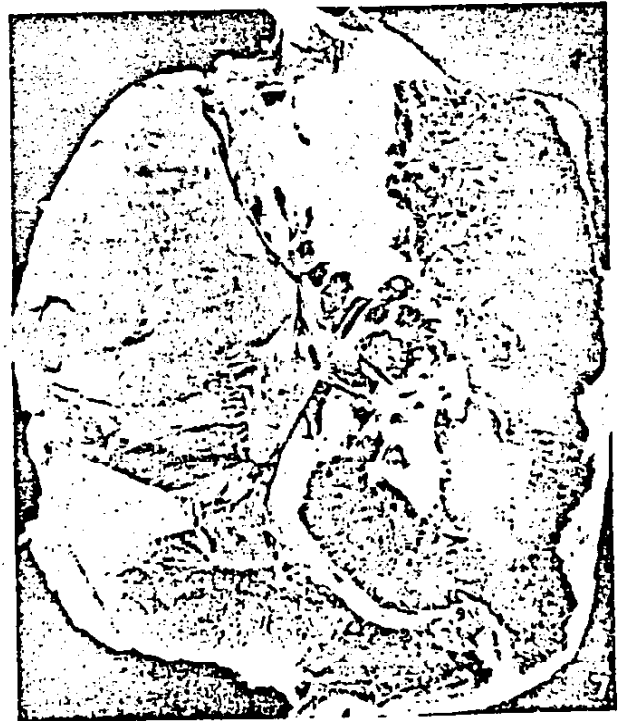

Fig. 7. Macroscopic specimen of mesothelioma of the pleura.

lobar fissures. It was never possible to define planes between the visceral pleura and the pathological tissue, so that separation was possible only by entering lung tissue. False planes could be developed through compressed peripheral lung. When the deep aspects of the peel were inspected, fine blackened fragments of lung were seen adhering to them. The tumours dipped into the lung substance along the interlobular septa and, for this reason, stripping along these false planes was halted every few millimetres. Inevitably, the procedure has to be abandoned, leaving a collapsed, tattered and leaking lung.

AUTOPSY FINDINGS

At autopsy the whole thoracic cavity may be occupied by a large gelatinous tumour, which displaces the mediastinum, and markedly compresses the lung (Fig. 7). In other cases the tumour may be dense and cartilaginous. In these advanced cases no remnant of a pleural space may remain. The tumour infiltrates adjacent structures, so that the pericardium, heart, chest wall, diaphragm and liver may form one solid mass. In 1 case the tumour extended into the posterior peritoneum, encasing a kidney. The mediastinal, cervical and para-aortic lymph glands may be involved and appear as large discrete tumours. The lung is always compressed, with marked lymphatic spread in some terminal cases. Because the neoplasm extends along the interlobar fissures, the lobes appear as 2 or 3 small deeply pigmented areas within a huge pinkish-white mass.

PROGNOSIS AND TREATMENT

Our first impressions, based upon the apparently fibrous nature of the tumour, was that it was slow-growing, but we found this to be far from true. According to Choptal *et al.*¹⁶ the average duration of life from the time of onset of symptoms is 18 months. Hochberg's review²⁹ of 43 cases showed that 37 (86%) died within the first year. Of the 34 patients discussed here, 28 have died, 17 (61%) within a year of the development of symptoms. Seven (25%) died during the second year, 2 (7%) during the third year, and all 28 were dead within 48 months, which is the longest survival time among our patients.

It has already been shown that operative removal of the growth is impossible and some form of chemo- or radio-active therapy would seem to provide the only hope of effective treatment. Results have been disappointing. Two patients were given repeated intrapleural injections of nitrogen mustard. Both men died within 6 months. Four patients, with seemingly localized areas of disease, were given deep-X-ray therapy. All were dead within a year. Six patients have had radio-active gold instillations. Four died within 13 months of the commencement of their injections and 2 are alive, but their treatment was recent. There seems little to be gained by subjecting patients to

the additional discomforts of present forms of therapy, but we still advise radio-active gold intrapleurally for the comparatively early case, where the lung retains some elasticity.

SUMMARY

The clinical and radiological findings of 34 patients suffering from diffuse pleural mesotheliomas are described. Thirty-three of these patients gave a history of exposure to crocidolite asbestos mined in the North West Cape. However, even when lung tissue was available, histological evidence of asbestosis was not obtained in every case. Asbestos bodies were found in the lung tissue of 30% of the cases.

The findings of this and our other paper¹ are sufficiently striking to justify further epidemiological and laboratory investigations. These investigations will attempt to determine the causative and correlative factors, including a possible relationship with asbestos or other elements especially in the regions from which the cases have most frequently been reported.

We wish to thank the many medical practitioners in the Griqualand West District, and the thoracic surgeons, physicians, radiologists and pathologists from elsewhere in the Union whose assistance has made this investigation possible.

We thank the Director of the Pneumoconiosis Bureau for permission to reproduce the X-ray plates shown in Figs. 3 and 4.

We thank the Secretary for Health for permission to publish this paper.

REFERENCES

1. Wagner, J. C., Sleggs, C. A. and Marchand, P. (1960): *Brit. J. Indust. Med.*, 17, 260.
2. Robertson, H. E. (1924): *J. Cancer Res.*, 82, 317.
3. Willis, R. A. (1953): *Pathology of Tumours*, 2nd ed. London: Butterworth.
4. Klemperer, P. and Rubin, C. B. (1931): *Arch. Path.*, 11, 355.
5. Stout, A. P. and Murray, M. R. (1942): *Ibid.*, 34, 951.
6. Tobiassen, G. (1955): *Acta path. microbiol. scand.*, suppl. 105, 198.
7. Bellini, G. and Bovo, G. (1957): *Acta med. patav.*, 17, 367.
8. Godwin, M. C. (1957): *Cancer*, 10, 295.
9. McCaughey, W. T. E. (1951): *J. Path. Bact.*, 76, 517.
10. Dible, J. H. (1959): Personal communication.
11. Gough, J. (1959): Personal communication.
12. Steiner, P. (1957): Personal communication.
13. Stewart, H. (1959): Personal communication.
14. Vorwald, A. (1959): Personal communication.
15. Daub, H. and Jones, H. (1942): *Radiology*, 39, 27.
16. Choptal, J., Campo, A., Jean, R. and Campo, C. (1956): *Poumon*, 12, 341.
17. Vermaas, F. H. (1952): *Trans. Geol. Soc. S. Afr.*, 55, 199.
18. Carroll-Porczynski, C. S. (1955): *Asbestos from Rock to Fabric*. Manchester: The Textile Institute.
19. Lynch, K. M. and Smith, W. A. (1935): *Amer. J. Cancer*, 24, 56.
20. Doll, R. (1955): *Brit. J. Indust. Med.*, 12, 31.
21. Merzweiler, E. R. A. (1954): Annual Report, Inspector of Factories, p. 191. London: Her Majesty's Stationery Office.
22. Cartier, P. (1952): *Arch. Indust. Hyg.*, 5, 262.
23. Van der Schoot, H. M. C. (1958): *Ned. T. Geneesk.*, 102, 1125.
24. Day, E. (1958): Personal communication.
25. Frost, J., Georg, J. and Muller, P. F. (1956): *Dan. Med. Bull.*, 3, 202.
26. Smith, A. R. (1952): *Amer. J. Roentgenol.*, 167, 375.
27. Hurwitz, M. (1959): In *Proceedings - Pneumoconiosis Conference 1959*. London: Churchill.
28. *Idem* (1960): Personal communication.
29. Hochberg, L. A. (1951): *Amer. Rev. Tuberc.*, 63, 150.

PASSING EVENTS : IN DIE VERBYGAAN

South African Institute for Medical Research, Johannesburg. Staff Scientific Meeting. The next meeting will be held on Monday 23 January at 5.10 p.m. in the Institute Lecture Theatre. Dr. L. Webster, of the Pneumoconiosis Research Unit, will speak on 'Pneumoconiosis problems'.

Southern Transvaal Branch (M.A.S.A.). An important general meeting of this Branch will be held at Medical House, 5

Esselen Street, Hospital Hill, Johannesburg, on Tuesday 17 January 1961 at 8.15 p.m. Reports will be presented by the President on the recent developments in connection with (a) medical insurance companies, (b) medical aid societies, and (c) the Medical Services Plan. The Domicile Clause in Section 24 of the Medical, Dental and Pharmacy Act will also be before the meeting for full discussion. Members of the Branch are urgently requested to attend this important meeting.

SOUTH

It is with that neg Society cannot b insured t ip. 1064 be treat rendered for the r

Chequ Mutual account insurance

When th insurance the medi They fix considere all done they app assist the

The F. In Marcl medical by insur down for of Couns companie providing the medi satisfied those per fundamer vision of and the l payment

At its agreed, at companie bers of n sponsore income i panies we all insur be regul. insurance rules to

Follow were helc took plac Committe insurance income e person b receive b satisfactio of SAN's member tive of t unfortun the rule any deci

The Se two sch The new did not ca Inter ali the fees